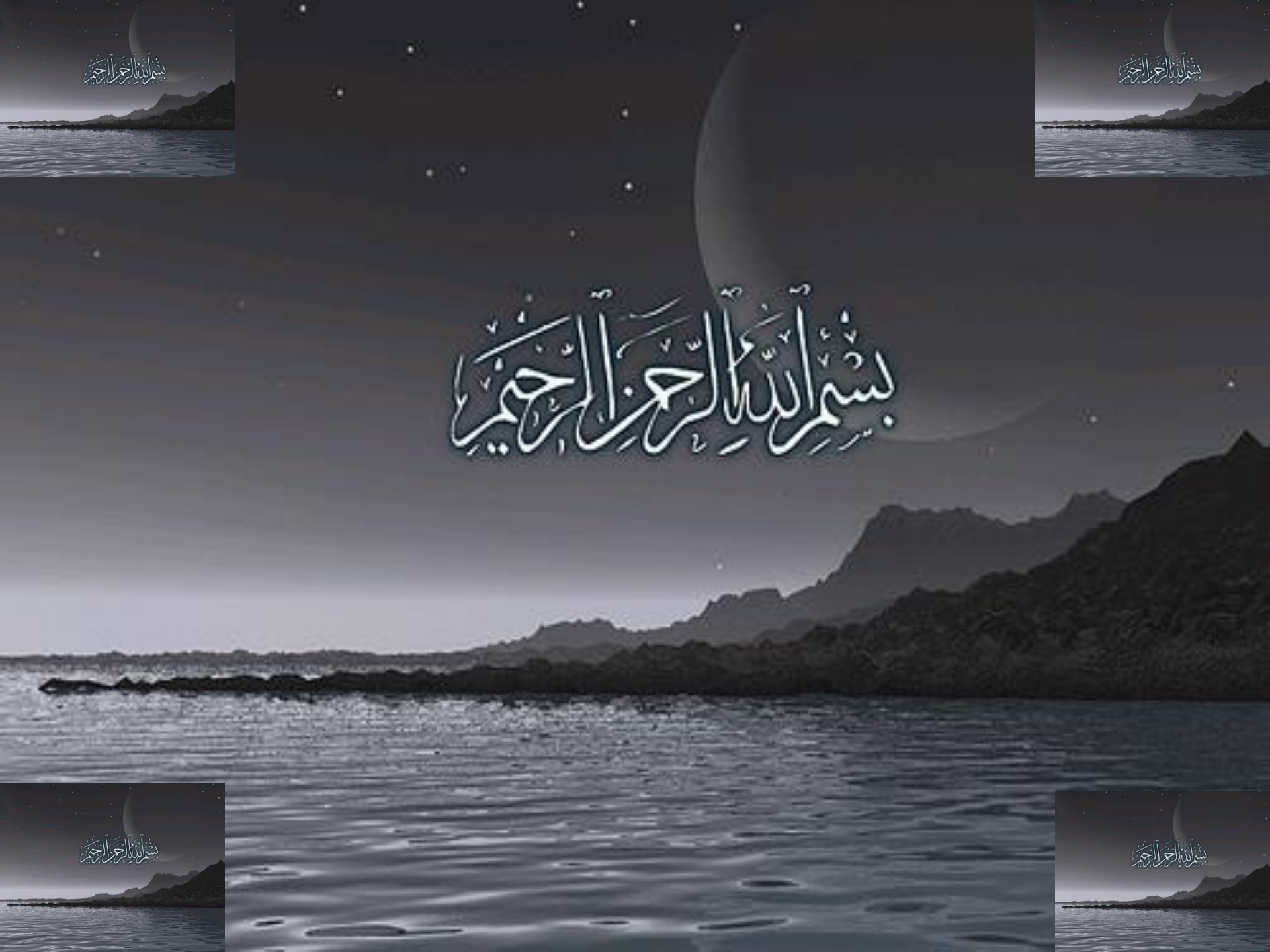



بِسْمِ اللَّهِ الرَّحْمَنِ الرَّحِيمِ

بِسْمِ اللَّهِ الرَّحْمَنِ الرَّحِيمِ

بِسْمِ اللَّهِ الرَّحْمَنِ الرَّحِيمِ

بِسْمِ اللَّهِ الرَّحْمَنِ الرَّحِيمِ

بِسْمِ اللَّهِ الرَّحْمَنِ الرَّحِيمِ

دکتر عبدالحسن کاظمی

دانشکده پزشکی دانشگاه علوم پزشکی تبریز

**Rhinocerebral mucormycosis &  
COVID - 19**

# Fungal Diseases, Rhinocerebral mucormycosis and COVID-19

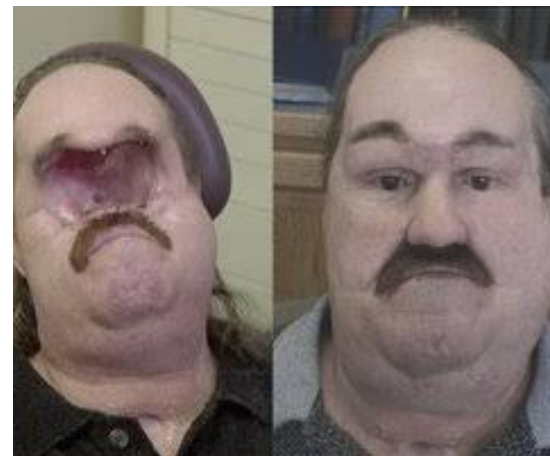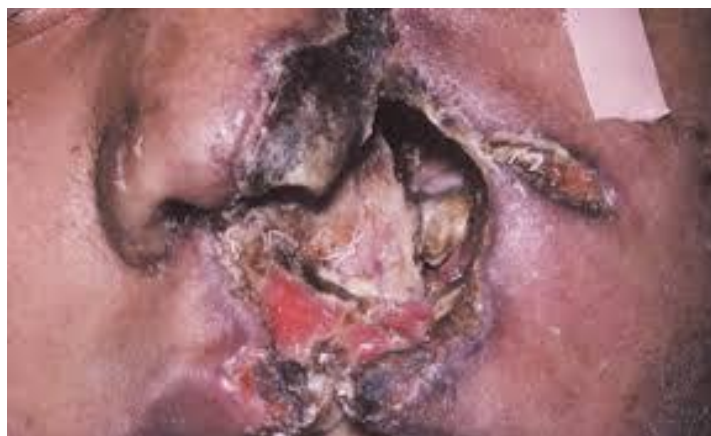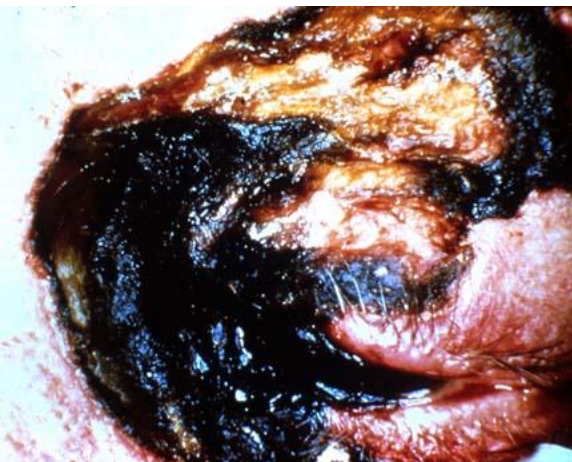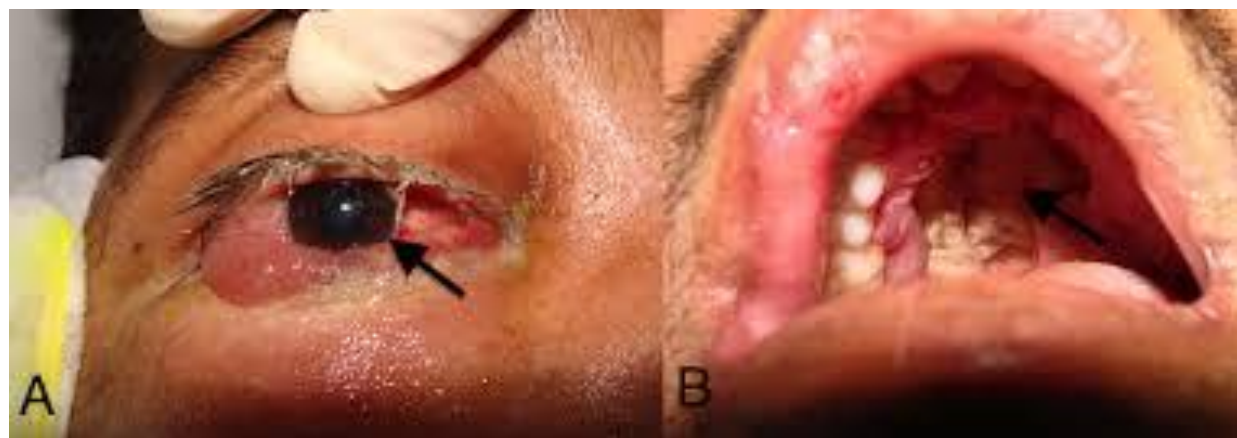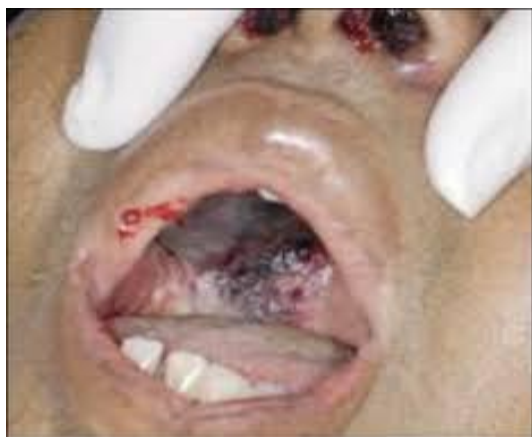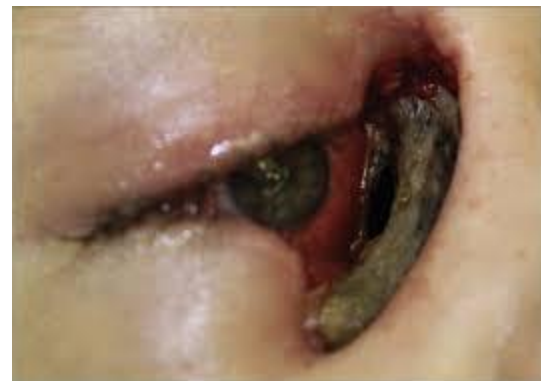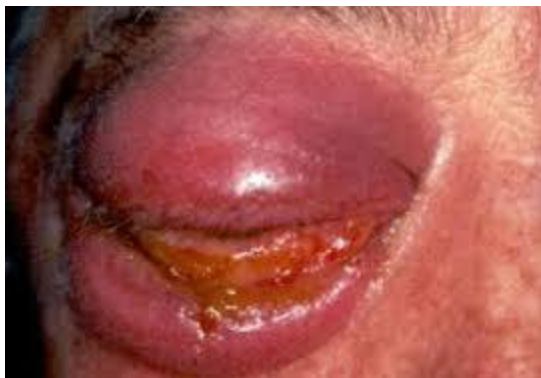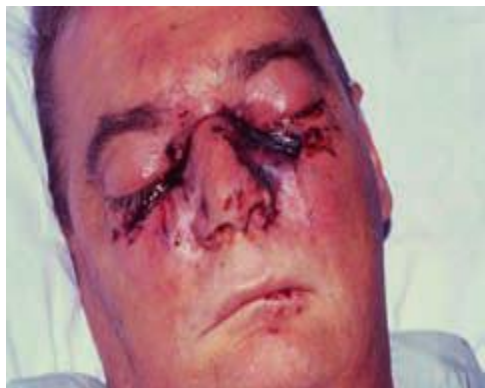<https://www.cdc.gov/fungal/covid-fungal.html>

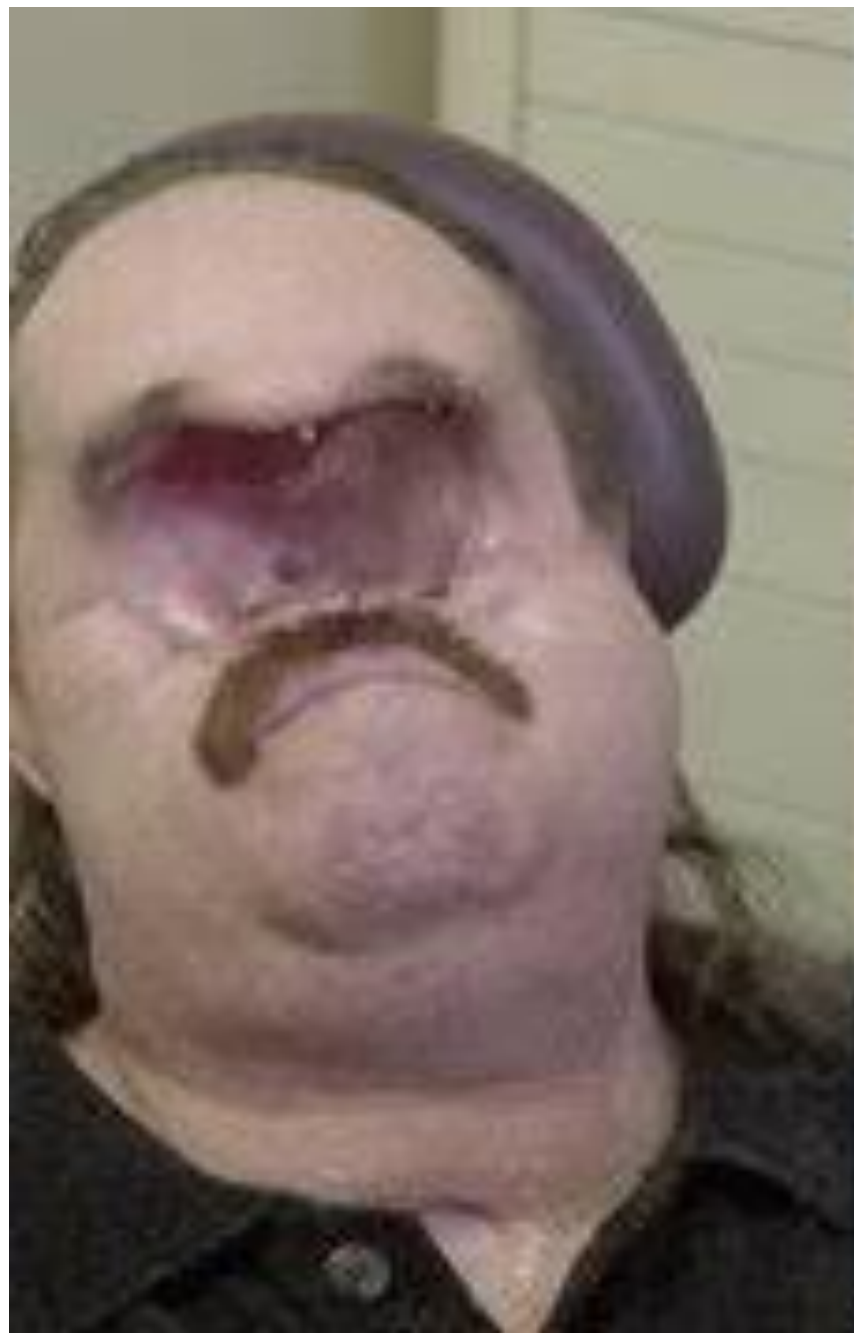## Overview

Symptoms of some fungal diseases can be similar to those of [COVID-19](#), including fever, cough, and shortness of breath.<sup>1</sup>

Laboratory testing is necessary to determine if a person has a fungal infection or COVID-19.

Some patients can have COVID-19 and a fungal infection at the same time.





# Overview

People with severe COVID-19, such as those in an intensive care unit (ICU), are particularly vulnerable to bacterial and fungal infections. The most common fungal infections in patients with COVID-19 include Mucormycosis, Aspergillosis, Invasive Candidiasis.<sup>[1](#)–[6](#)</sup>

These fungal co-infections are reported with increasing frequency and can be associated with severe illness and death.

Awareness of the possibility of fungal co-infection is essential to reduce delays in diagnosis and treatment in order to help prevent severe illness and death from these infections.

# AIRBORNE FUNGI IN TABRIZ, COMPARING AIRBORNE AND CLINICAL SAMPLES OF A. FUMIGATUS (2011), SURVEY AND LITERATURE REVIEW

[KAZEMI ABDOLHASSAN](#), [AHMADPOUR EHSSAN](#), [NAGHILI BEHROZ](#), [ZAREI MAHMOUDABADI ALI](#), [JAFARI ABBASALI\\*](#), [MOUSAVI AYATOLLAHI AMIN\\*](#) [JUNDISHAPUR JOURNAL OF MICROBIOLOGY \(JJM\)](#) [2013](#) , Volume 6 , Number 4 (S.N. 22); Page(s) 1 To 5. Paper

DEPARTMENT OF MEDICAL MYCOLOGY, SCHOOL OF MEDICINE, SHAHID SADOUGHI UNIVERSITY OF MEDICAL SCIENCES, YAZD, IR IRAN

**Abstract:** Background: Air contamination with fungal spores and the presence of these spores on respiratory tract, especially in industrialized cities with contaminated air, can play an important role on the occurrence of respiratory and coetaneous mycoses, asthma and allergic reactions. This survey was carried out to determine the prevalence of different fungal spores in the atmosphere of Tabriz district.

**Objectives:** The present study aimed to detect fungal air spores in Tabriz environments, and to compare the environmental samples of *Aspergillus fumigatus* with the clinical isolated samples of this fungus, due to the importance of the dangers of *A.fumigatus* for public health, particularly for the immunocompromised patients.

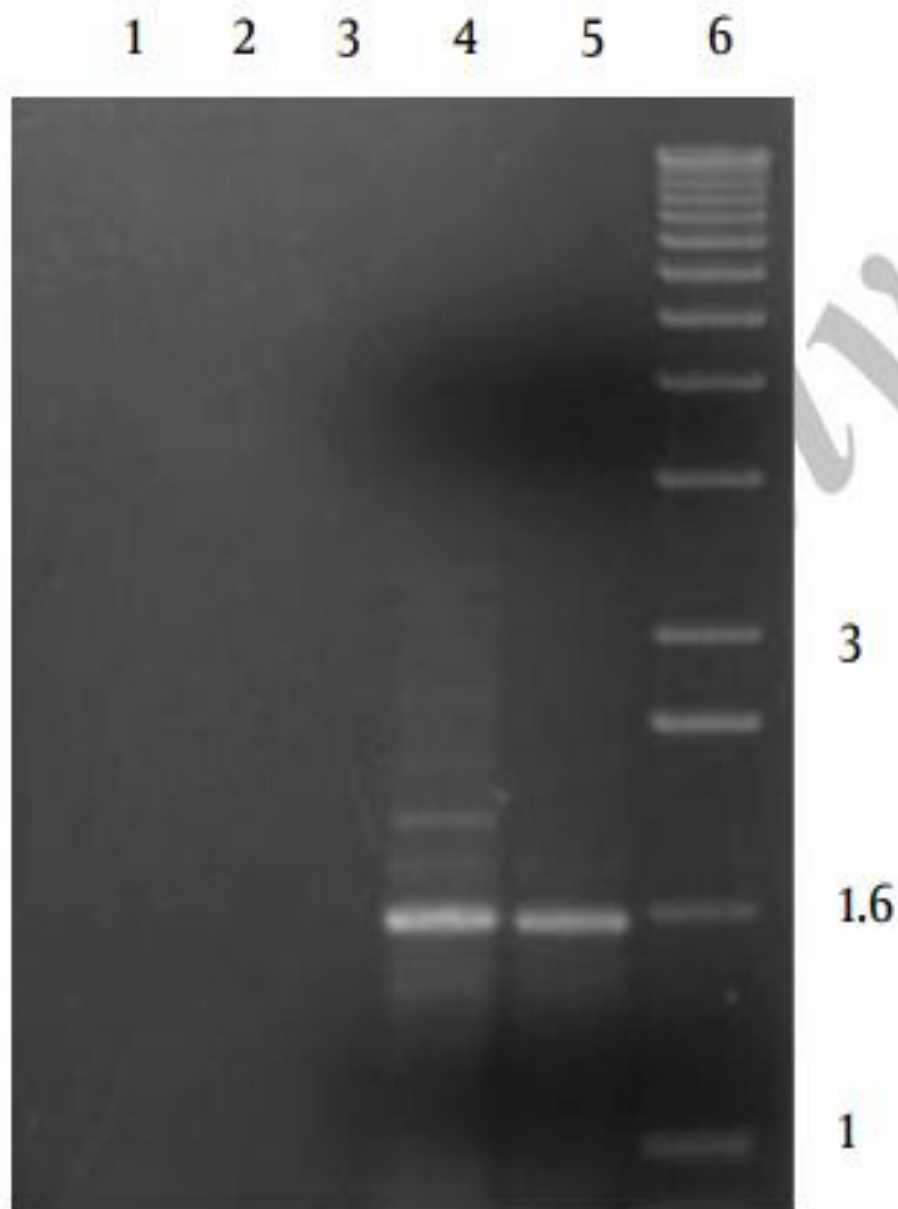
**Materials and Methods:** During this survey, the presence of air fungal spores was analyzed using settle plate and prepared culture in Sabouraud's dextrose agar. Prior identifications were performed using macroscopic characters, and direct microscopy. 262 samples were collected from different areas of the atmosphere of Tabriz district within all four seasons of the year. Fungal colonies were isolated from all air samples and identified using macroscopic and microscopic characters, and slid culture.

**Results:** The main isolated fungal spores from the atmosphere of Tabriz district were *Penicillium* Sp. (36.6%), *Cladosporidium* Sp. (26.8%) and *Aspergillus* Sp. (23.6%).

**Conclusions:** The presence of fungal spores in the atmosphere as a part of air pollution can cause significant problems for human health, particularly in the respiratory tracts.

**Keyword(s):** FUNGI, SPORES, FUNGAL, TABRIZ, ASPERGILLUS FUMIGATUS

**Figure 2.** Gel Electrophoresis of PCR Products Using Degenerate Primers



**Table 1.** Colony Count and Percentage of the Identified Fungi

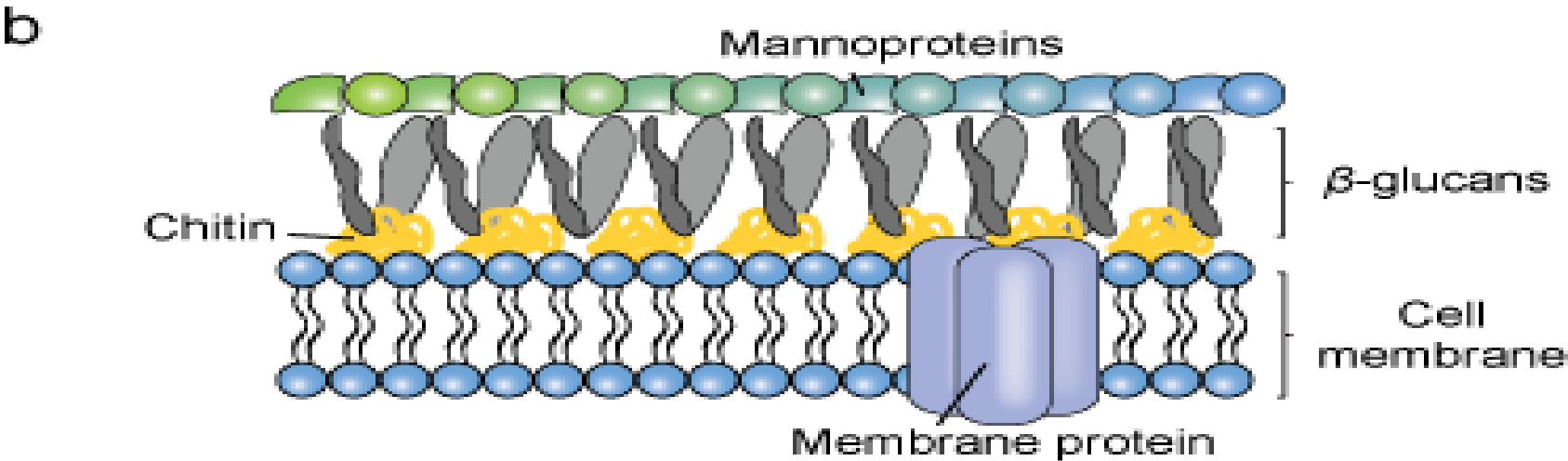
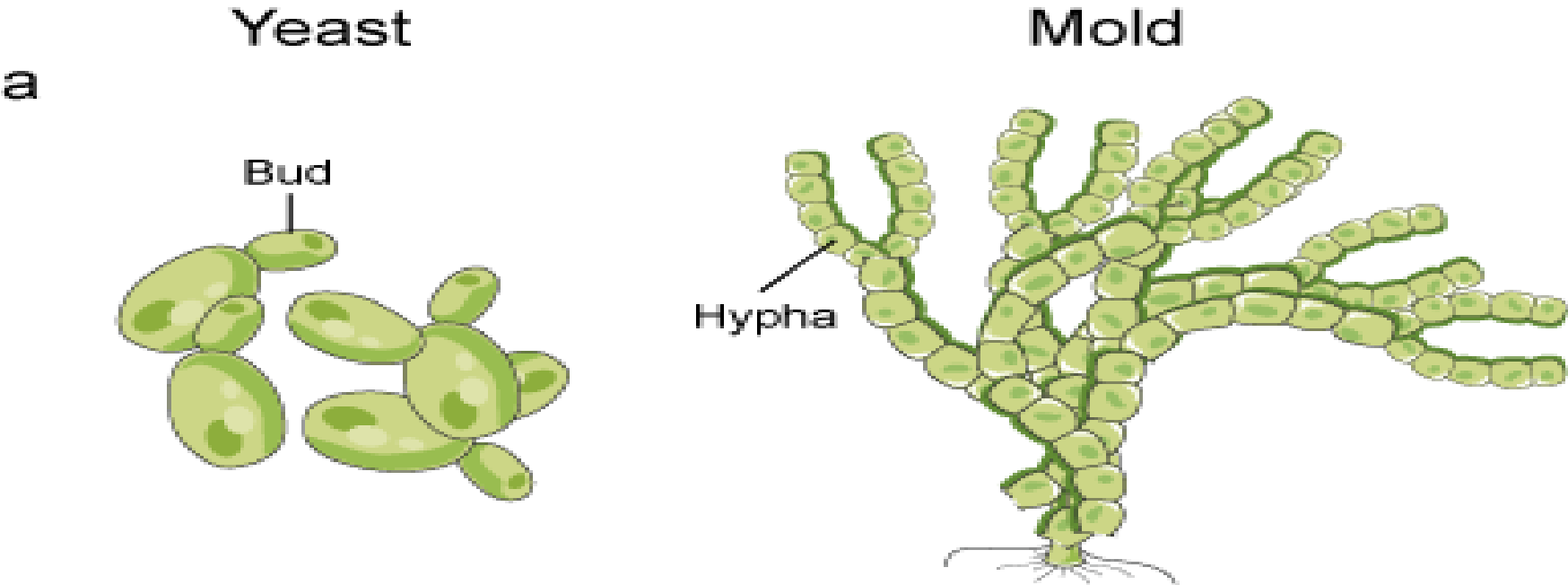
Fungi	Percentage	Colony Count
<i>Penicillium Sp.</i>	39.6	104
<i>Cladosporidium Sp.</i>	26.8	70
<i>Aspergillus Sp.</i>	23.6	62
<i>Tichoderma Sp.</i>	5.1	14
Yeast	2.8	4
<i>Chrysosporium Sp.</i>	0.7	2
<i>Fusarium Sp.</i>	0.7	2
<i>Alternaria Sp.</i>	0.7	2
<i>Acremonium Sp.</i>	0.7	2
<b>Total</b>	<b>100</b>	<b>262</b>

## 5. Discussion

Fungi can both degrade the organic materials and structures of their colonies, and contribute to the appearance of symptoms and diseases in the inhabitants of contaminated homes, hospitals, factories, etc. (8, 9). Citizens in city environments are not only at risk of harm to their health through environmental degradation as a result of the worsening air pollution problems such as fungal spores, but are also constantly threatened by emerging and recurring asthma, rhinitis, bronchopulmonary disorders, mycoses and hypersensitivity pneumonitis eni





# Structure of Fungi



# Risk Factors for Mucormycosis in COVID-19 Patients

## AUTHORS

Zahra Taghinejad <sup>1</sup>, Mohammad Asgharzadeh <sup>2</sup>, Vahid Asgharzadeh<sup>3</sup>, Abdolhassan Kazemi <sup>4,\*</sup>



**1** Hematology and Oncology Research Center, Tabriz University of Medical Sciences, Tabriz, Iran

**2** Biotechnology Research center and Faculty of Paramedicine, Tabriz University of Medical Sciences, Tabriz, Iran

**3** Student Research Committee, Tabriz University of Medical Sciences, Tabriz, Iran

**4** Medical Philosophy and History Research Center, Tabriz University of Medical Sciences, Tabriz, Iran

\* Medical Philosophy and History Research Center, Tabriz University of Medical Sciences, Tabriz, Iran. Email: [kazemi1338@gmail.com](mailto:kazemi1338@gmail.com)

## ARTICLE INFORMATION

▶ *Jundishapur Journal of Microbiology*: 14 (8); e117435

▶ **Published Online**: September 12, 2021


▶ **Article Type**: Review Article

▶ **Received**: June 28, 2021

▶ **Revised**: August 30, 2021

▶ **Accepted**: September 05, 2021

▶ **DOI**: [10.5812/jjm.117435](https://doi.org/10.5812/jjm.117435)



**Crossmark**  
CHECKING

**How to Cite:** Taghinejad Z, Asgharzadeh M, Asgharzadeh V, Kazemi A. Risk Factors for Mucormycosis in COVID-19 Patients. *Jundishapur J Microbiol.* 2021;14(8):e117435. doi: [10.5812/jjm.117435](https://doi.org/10.5812/jjm.117435).

# Mucormycosis

Mucormycosis (previously called zygomycosis) is a serious but rare fungal infection caused by a group of molds called mucormycetes. These molds live throughout the environment.

Mucormycosis mainly affects people who have health problems or take medicines that lower the body's ability to fight germs and sickness.

It most commonly affects the sinuses or the lungs after inhaling fungal spores from the air. It can also occur on the skin after a cut, burn, or other type of skin injury.

## موکور میکوزیس

- موکور میکوزیس بیماری حاد و نسبتاً کشنده است که به سرعت توسعه می یابد و به علت قارچهای مختلف راسته موکورال ایجاد می گردد.
- بیماری به اشکال رینوسربزال، ریوی، گاستروانتستینال، جلدی و یا منتشره دیده می شود.
- این عوامل به طور معمول بیماریزا نمی باشند، بیماریهای ناتوان کننده ای چون دیابت بخصوص در مرحله کنترل نشده و اسیدوز، لوسمی، سل، سوختگی و سوء تغذیه زمینه را برای ابتال به بیماری فراهم می سازند.
- این قارچها علاقه خاص در تهاجم به عروق خونی دارند. ضایعات اغلب با واکنشهای نکروزه و چرکی همراه می باشند و تولید گرانولوم شایع نیست.

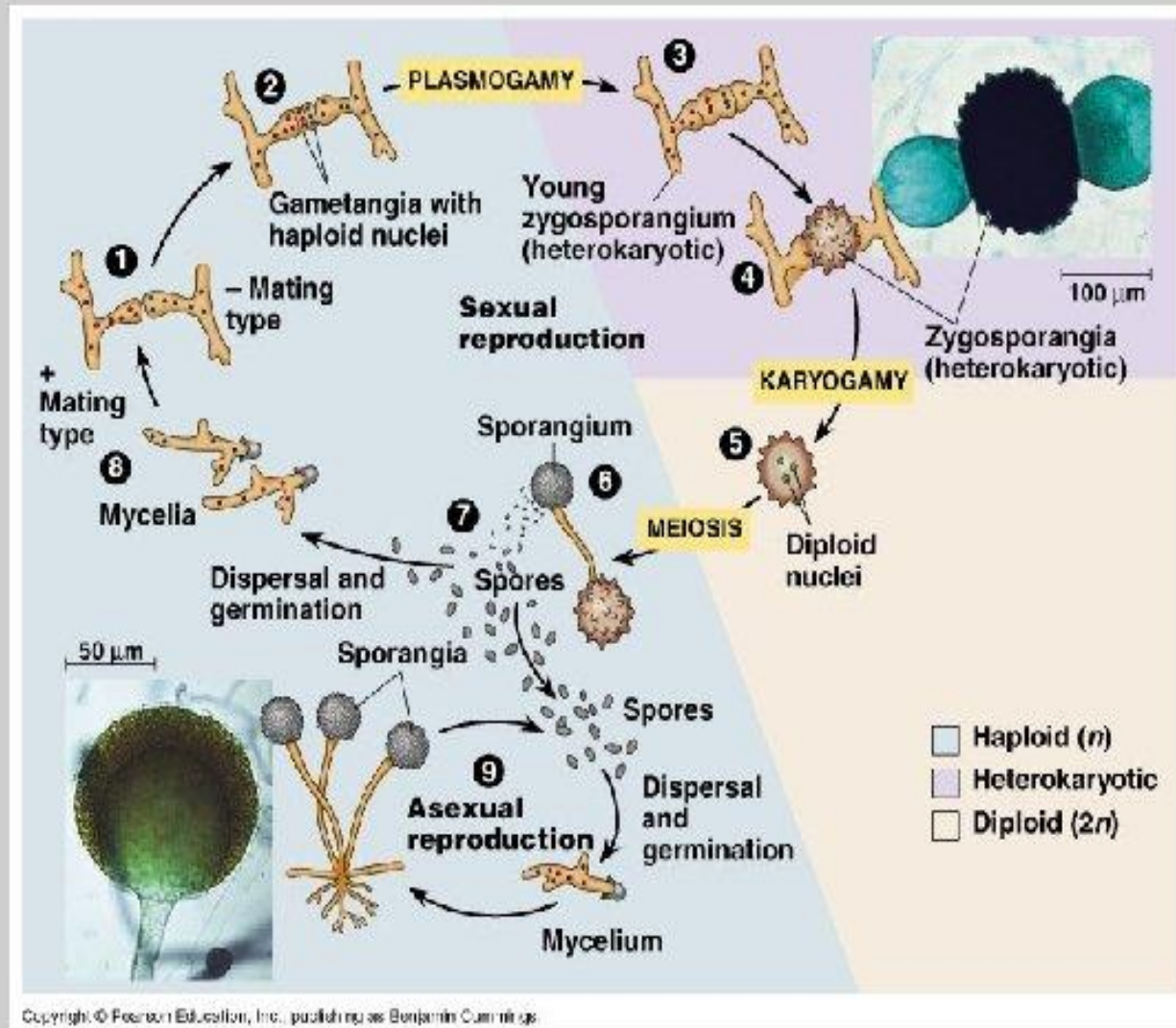
## عوامل بیماری

• ارگانیس‌های عامل بیماری متعلق به راسته موکورال و رده زیگومیست می باشند مهمترین جنس‌های موکورمیکوز انسان عبارتند از:

- Syncephalastrum
- Mucor
- Absidia
- Rhizopus
- Rhizomucor
- Mortierella

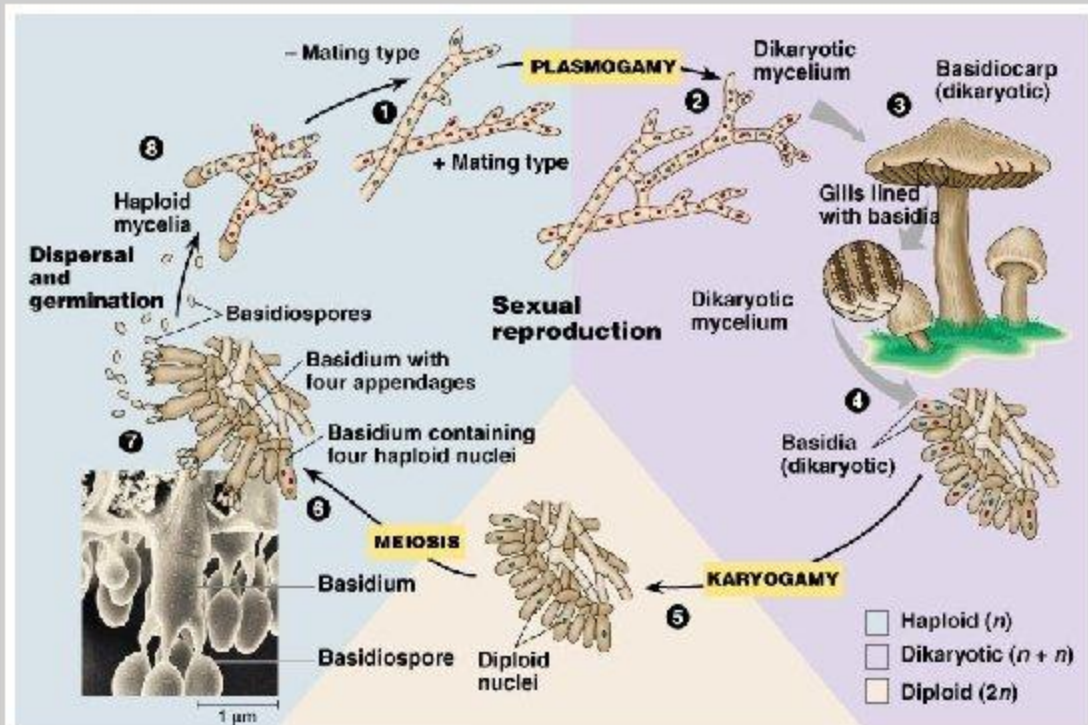
# B. Zygomycota

1. No dikaryotic growth
2. Both sexual and asexual sporangia



# D. Basidiomycota - Life cycle

1. Dikaryotic growth
2. Fruiting body: basidiocarp
3. Fertile layer on gills with basidia (“clubs”)
4. Four spores per basidium
5. Asexual reproduction is rare



# Why Deadly 'Black Fungus' Is Ravaging

## COVID Patients in India

Standard treatments such as steroids, as well as illnesses such as diabetes, make the fungal infection worse [@Scientific American](#)



# COVID-19-associated mucormycosis

COVID-19–associated mucormycosis is less common than other COVID-19–associated fungal infections<sup>24</sup>, but emerging reports from India highlight the importance of considering this infection. Some medications used to treat severe COVID-19, including high-dose corticosteroids and tocilizumab, might predispose patients with COVID-19 to mucormycosis.

Mucormycosis has been reported in patients with severe COVID-19 infection who lacked other classical mucormycosis risk factors, such as diabetes, conditions or medications that weaken the immune system, and cancer.<sup>25,26</sup>

Early diagnosis and treatment are key to improving outcomes for patients with COVID-19–associated mucormycosis. Clinicians should consider the possibility of mucormycosis in patients with severe COVID-19 even when patients lack classical risk factors for this disease.

Biomarkers for diagnosing invasive aspergillosis, such as beta-d-glucan and galactomannan, are typically negative in patients with mucormycosis. The treatment for mucormycosis frequently involves aggressive surgical intervention and treatment with antifungals, including amphotericin B, posaconazole, or isavuconazole.

**Voriconazole is not recommended for treating mucormycosis.**<sup>27</sup>

# How common is mucormycosis?

Mucormycosis is rare, but the exact number of cases is difficult to determine because no national surveillance exists in the United States. Population-based incidence estimates for mucormycosis were obtained from laboratory surveillance in the San Francisco Bay Area during 1992–1993 and suggested a yearly rate of **1.7 cases per 1 million** population. <sup>1</sup>

Prospective surveillance among 16,808 transplant recipients performed in 23 institutions during 2001–2006 found that mucormycosis was the third most common type of invasive fungal infection in **stem cell transplant recipients** and accounted **for 8% of all invasive fungal infections** (77 mucormycete cases occurred among 983 stem cell transplant recipients who developed any fungal infection). <sup>2,3</sup> Among solid organ transplant recipients, **mucormycosis accounted for 2% of all invasive fungal infections** (28 mucormycete cases occurred among 1,208 solid organ transplant recipients who developed any fungal infection). <sup>3,4</sup>

The number of cases varied widely across participating institutions.

# Mucormycosis outbreaks

Healthcare providers who are concerned about an unusual number of new cases should contact their state or local public health agency.

Although most cases of mucormycosis are sporadic (not part of an outbreak), outbreaks of mucormycosis have occurred. In healthcare settings, it can be difficult to determine whether mucormycosis is healthcare-associated or whether the infections were acquired somewhere else.

Some examples of sources implicated in healthcare-associated mucormycosis outbreaks include adhesive bandages, wooden tongue depressors, **hospital linens**, negative pressure rooms, water leaks, **poor air filtration, non-sterile medical devices, and building construction.** [7-14](#)

Community-onset outbreaks have been associated with trauma sustained during natural disasters. [15](#)

# Deaths due to mucormycosis

Mucormycosis is frequently a life-threatening infection. A review of published mucormycosis cases found an overall all-cause mortality rate of 54%.<sup>8</sup>

The mortality rate varied depending on underlying patient condition, type of fungus, and body site affected (for example, the mortality rate was 46% among people with sinus infections, 76% for pulmonary infections, and 96% for disseminated mucormycosis).<sup>8</sup>

# The perfect storm

## COVID-19 Resource Center

Breaking news and emerging research on the COVID-19 pandemic.

The combination of COVID-19, corticosteroid therapy and diabetes creates the perfect storm in which mucormycosis takes roots and thrives. Corticosteroids are a life-saving treatment used to reduce the dysregulated immune response observed in patients with COVID-19. However, **they increase the blood sugar level, and fungi enjoy the sugar**, Natarajan said. Hyperglycemia in patients with diabetes creates an even more favorable environment.

“Diabetes affects many people in India and, due to the weakened immune system, predisposes to more severe COVID-19 infection, which is typically treated with corticosteroids. With this combination of dysfunctional immune system — that is, a common denominator of COVID-19 and **diabetes — plus the use of corticosteroids, the risk of mucormycosis increases exponentially,**” Natarajan said.

In addition, COVID-19 damages and weakens the superior respiratory tract and the eye, increasing susceptibility to fungal infection. Another contributing factor is the use of antibiotics, also commonly prescribed in patients with COVID-19 to fight secondary infections, he said.

# Symptoms of Mucormycosis

The symptoms of mucormycosis depend on where in the body the fungus is growing. [1,4](#)

Symptoms of **rhinocerebral (sinus and brain) mucormycosis** include:

One-sided facial swelling

Headache

Nasal or sinus congestion

Black lesions on nasal bridge or upper inside of mouth that quickly become more severe  
Fever

**Disseminated mucormycosis** typically occurs in people who are already sick from other medical conditions, so it can be difficult to know which symptoms are related to mucormycosis.

Patients with disseminated infection in the brain can develop mental status changes or coma.

## تظاهرات بالینی

- حادثترین عفونت قارچی شناخته شده است.
- بیشتر موارد بیماری در افراد دیابتی کنترل نشده در مرحله اسیدوز، بچه های مبتال به سوء تغذیه، بیماران با سوختگی شدید، افراد مبتال به سرطان و درمان دارویی با داروهای سرکوب کننده سیستم ایمنی و کورتیکواستروئیدی دیده می شود.
- در زایگومایکوزیس ناشی از راسته موکوراتال برخلاف راسته انتموفتوراتال که ضایعات گرانولوماتوزی ایجاد می کنند، التهاب دیده نمی شود.
- بیماری موکورمیکوزیس به اشکال بالینی مختلفی بروز می کند.

## تظاهرات بالینی

• اشکال بالینی بیماری در ارتباط با بیماری

زمینه ای است.

فرم رینوسربرال در ارتباط با اسیدوز دیابتی

فرم ریوی در ارتباط با لوسمی و لنفوم □ فرم

گاسترواینستینال در ارتباط با سوء تغذیه



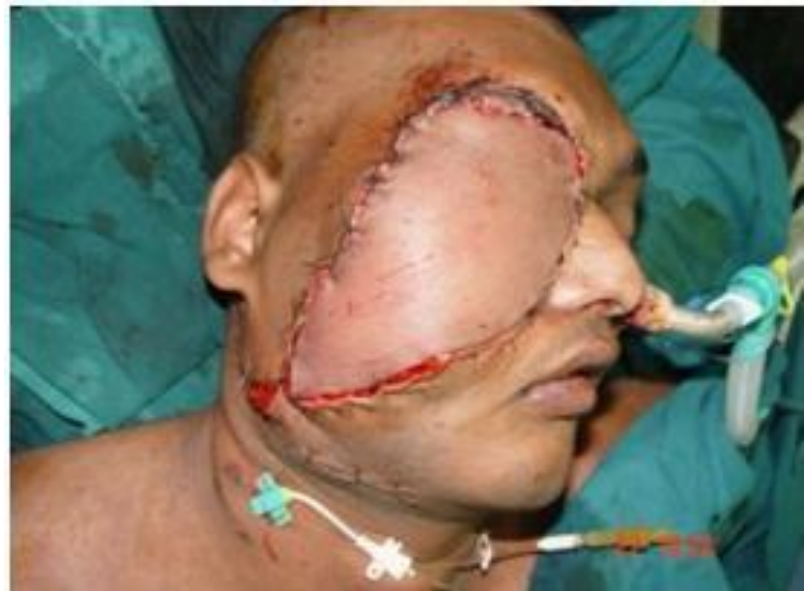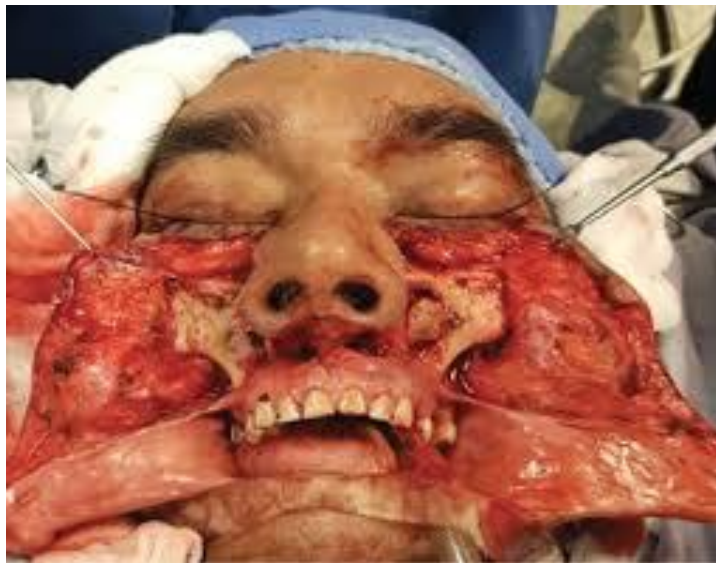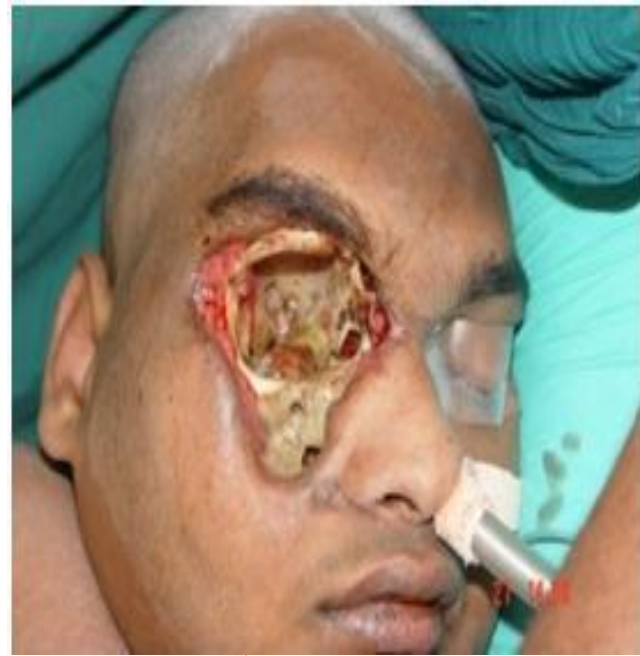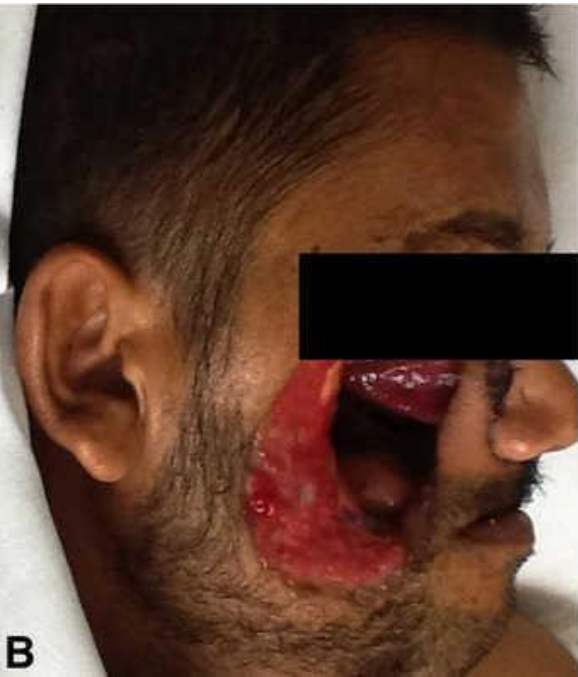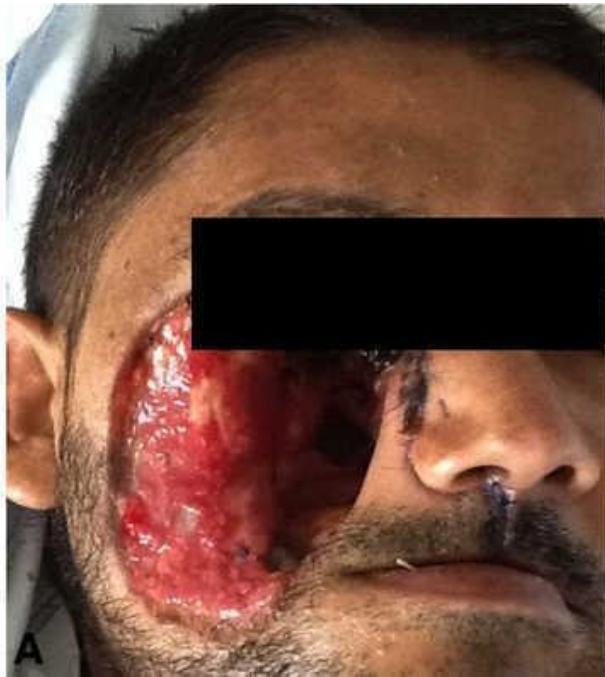## تظاهرات بالینی

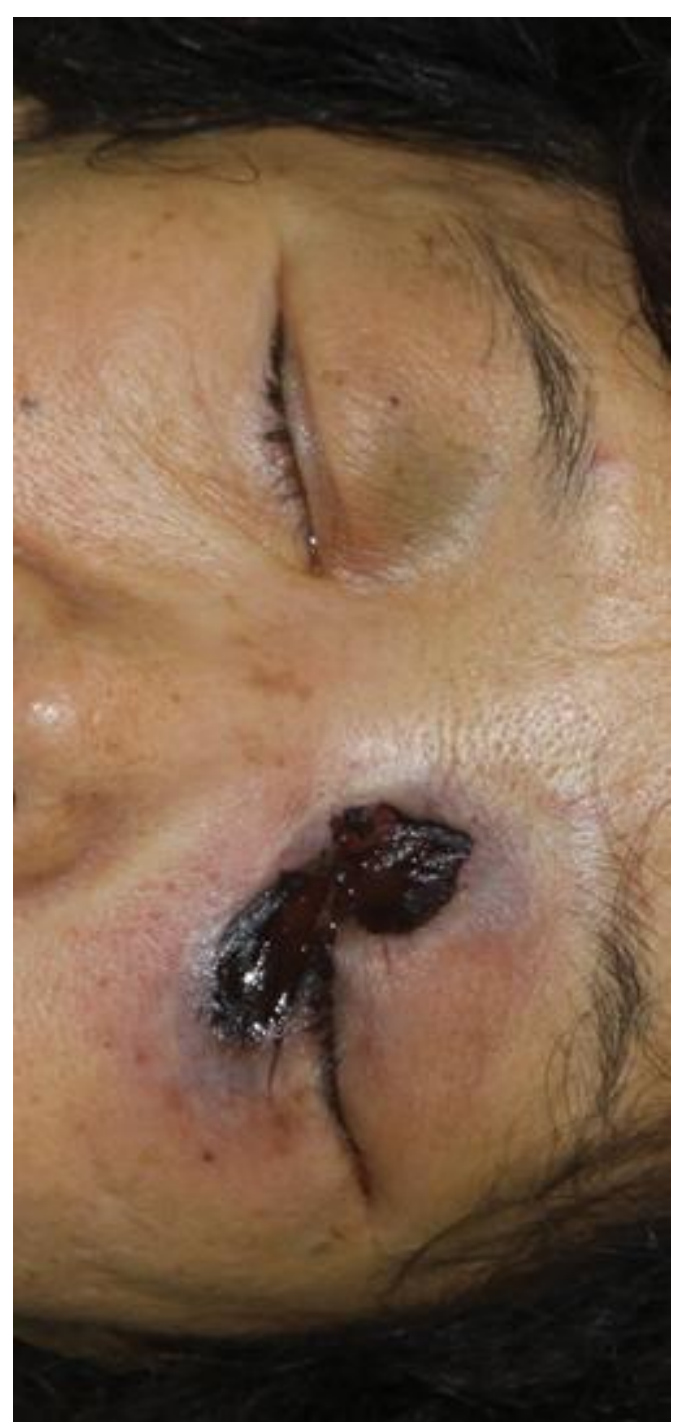
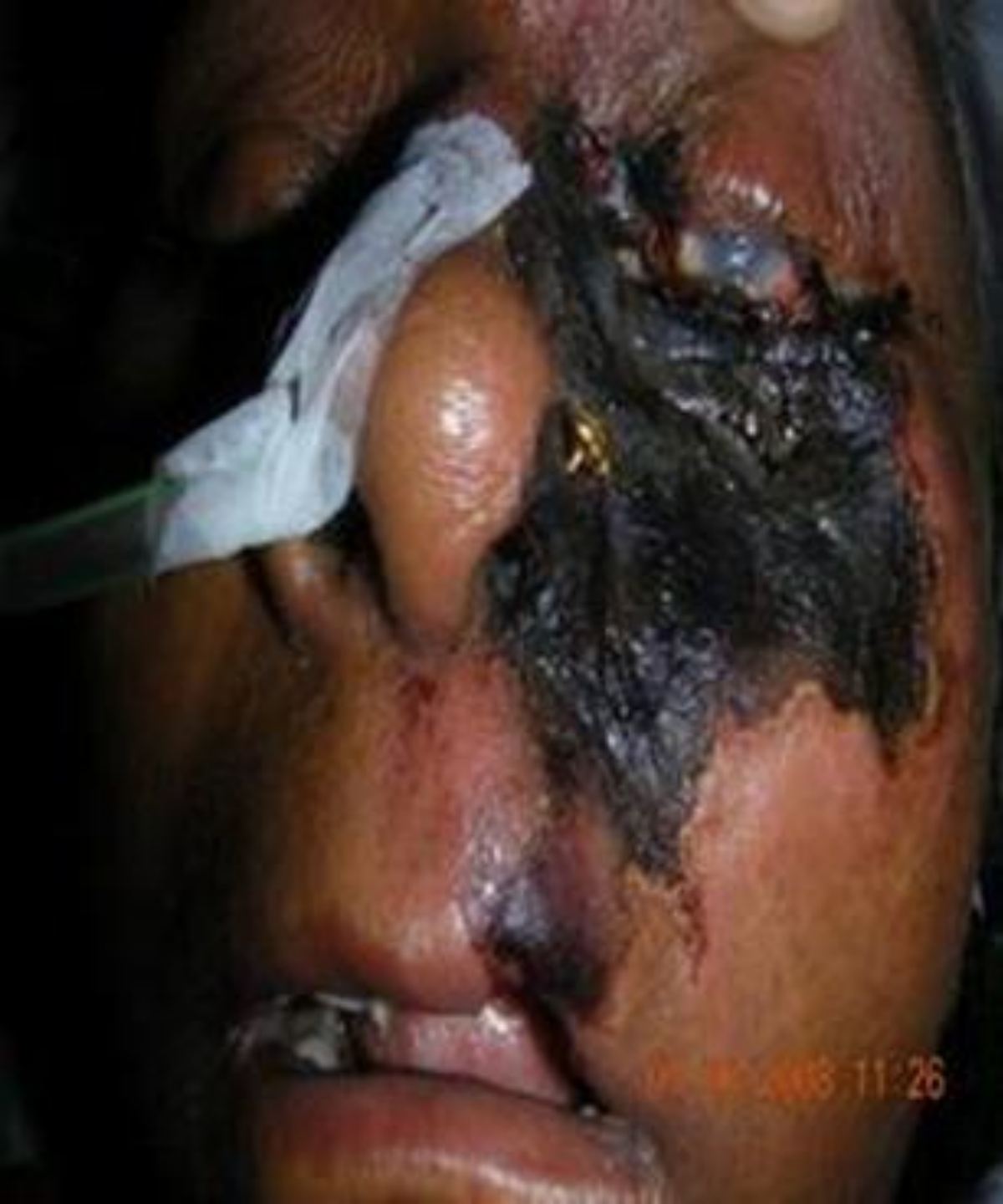• ماکور میکوزیس رینوسربرال:

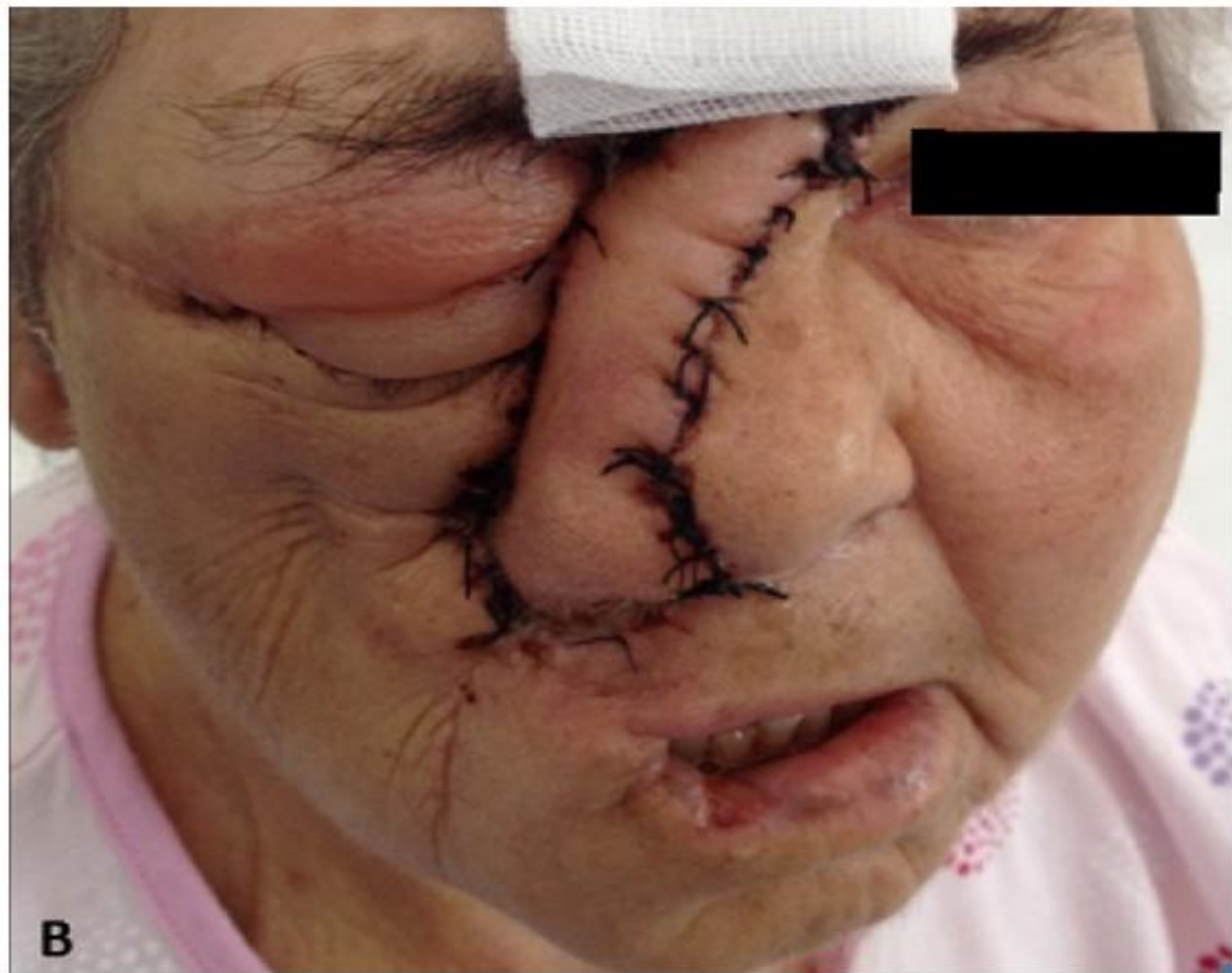این فرم بیماری اغلب با دیابت حاد در رابطه است و اگر تشخیص داده نشود به سرعت منجر به مرگ می گردد.

این شکل بیماری بیشتر در اثر گونه های ریزوپوس ایجاد می شود، عفونت از قسمتهای فوقانی شاخکهای بینی یا سینوسهای پارانازال و یا در موارد نادری از طریق حلق با سلولیت شروع میشود.

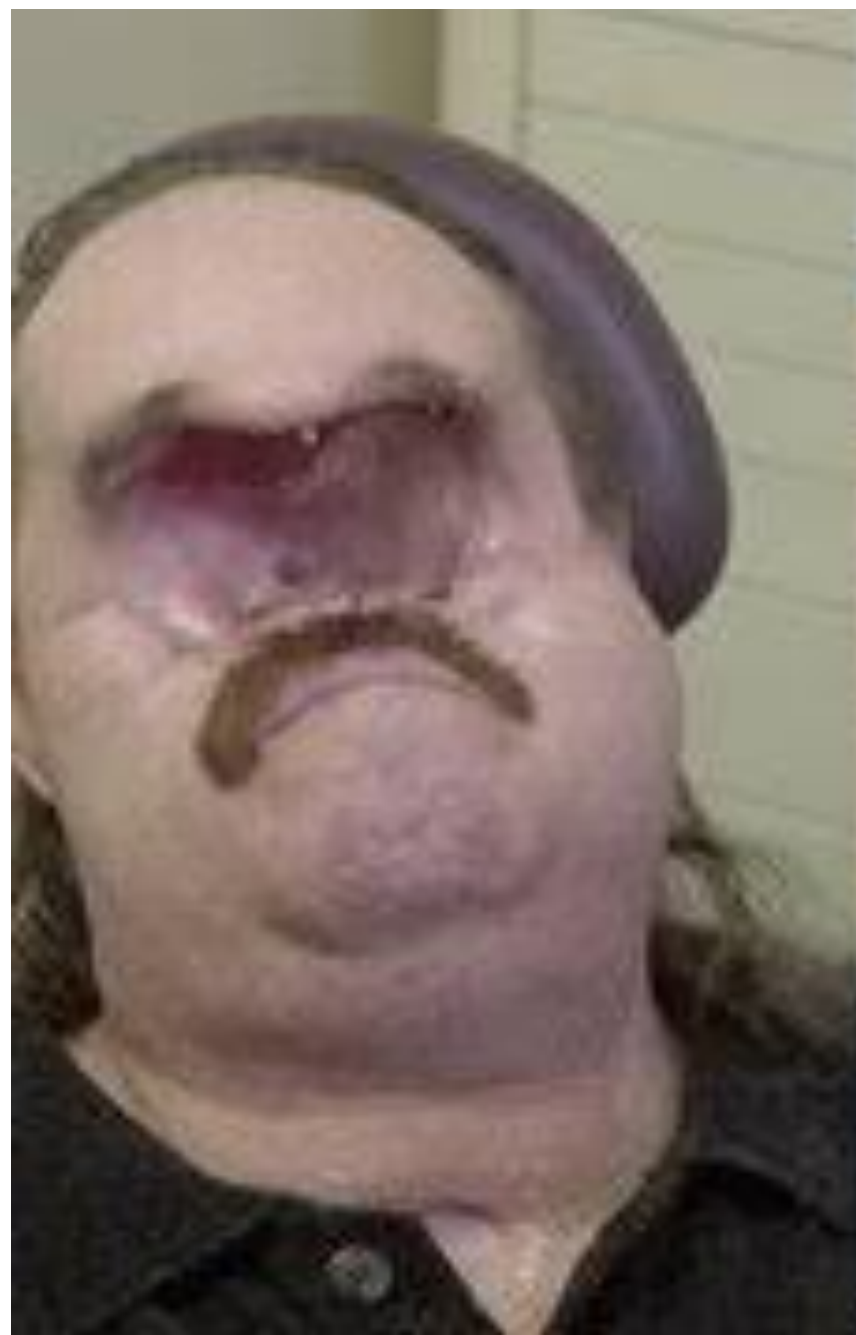
کنترل مرحله اسیدوز منجر به بهبودی موقت خودبخود در این بیماران میگردد محل عفونت بینی، کاسه چشم و در مراحل بعدی مغز و مننژ است.







**B**



## تشخیص افتراقی

- سایر عفونت های فرصت طلب
- عفونت های حاد باکتریال و ویروسی

# Treatment

Early recognition, diagnosis, and prompt administration of appropriate antifungal treatment are important for improving outcomes for patients with mucormycosis. [2](#)

Amphotericin B, posaconazole, and isavuconazole are active against most mucormycetes.

Lipid formulations of amphotericin B are often used as first-line treatment.

Medications active against *Aspergillus* such as voriconazole are not active against mucormycetes, and there is some evidence to suggest that pre-exposure to voriconazole may be associated with increased incidence of mucormycosis in some patients. [26,27](#)

In addition, surgical debridement or resection of infected tissue is often necessary, particularly for rhinocerebral, cutaneous, and gastrointestinal infections. [2,4](#) Control of the underlying immunocompromising condition should be attempted when possible. [2](#) The efficacy of other treatments such as hyperbaric oxygen therapy is uncertain but have been useful in certain situations. [28](#)

## درمان

- در درمان موکورمیکوزیس کنترل دیابت یا سایر عوامل مساعد کننده بیماری واجد اهمیت فراوان می باشد و در غیر این صورت درمان با داروهای ضدقارچی به تنهایی یا موثر نیست و یا اثر موقت دارد..
- آمفوتریسین B به طور سریع و با حداکثر دوز قابل تحمل در روز از راه تزریق وریدی تجویز می شود.
- جراحی ضایعات نکروتیک در موکورمایکوزیس جلدی یا برداشتن بافت نکروزه عفونی
- ترکیبات آزولی جدید در درمان موکورمیکوزیس چندان موثر نمی باشد



## تشخیص آزمایشگاهی

آزمایش مستقیم:

چون عوامل موکورمیکوزیس در طبیعت شایع می باشند در ترشحات ، خلط و سطح پوست نیز به طور آزاد وجود دارند و اغلب در محیطهای کشت نیز به سرعت رشد می نمایند، لذا انجام آزمایش مستقیم نسبت به کشت در تشخیص بیماری از اهمیت بیشتری برخوردار است.

• در نمونه شفاف شده خلط با محلول هیدروکسید پتاسیم هیفهای منشعب عریض با دیواره ضخیم به قطر 3 تا 25 میکرومتر و گاه تا 30 میکرومتر مشاهده می گردد.

• کشت:

• کلیه عوامل بیماریزا در موکورمیکوزیس در روی محیط S بدون سیکلو هگزیمید به خوبی قادر به رشد هستند.

• کلنی این قارچها رشد بسیار سریع دارد.

• کشت نمونه های بینی، کام و خلط به ندرت مفید است.

# Increased spread of *Candida auris* during COVID-19 pandemic

*Candida auris* is an emerging fungus that can cause outbreaks of severe infections in healthcare facilities. In the United States, it has most commonly spread in long-term care facilities caring for people with severe medical conditions. However, since the start of the COVID-19 pandemic, outbreaks of *C. auris* have been reported in COVID-19 units of acute care hospitals.

These outbreaks may be related to changes in routine infection control practices during the COVID-19 pandemic, including limited availability of gloves and gowns, or reuse of these items, and changes in cleaning and disinfection practices.

New *C. auris* cases without links to known cases or healthcare abroad have been identified recently in multiple states, suggesting an increase in undetected transmission. Screening for *C. auris* colonization, an important part of containment efforts, has been more limited as resources of healthcare facilities and health departments have been diverted to respond to COVID-19.

# Invasive candidiasis in patients with COVID-19

## Invasive candidiasis in patients with COVID-19

Patients hospitalized for COVID-19 are at risk for healthcare-associated infections (HAIs), including [candidemia](#), or bloodstream infections caused by *Candida*.<sup>7,17-19</sup> Fungal infections resistant to antifungal treatment have also been described in patients with severe COVID-19.<sup>19,20</sup> Early diagnosis and monitoring for *Candida* infections and antifungal resistant infections (e.g., *C. auris*, azole-resistant *Aspergillus*) are key to reducing death from COVID-19 in patients with severe COVID-19 fungal co-infections.

# Fungal pneumonias can resemble COVID-19

Other fungal diseases, such as histoplasmosis, Valley fever (coccidioidomycosis), and blastomycosis, can cause fever, cough, and shortness of breath, similar to COVID-19 and bacterial pneumonias.<sup>[21](#)</sup>

These fungi live in soil. People become infected by breathing in fungi present in the air. Clinicians should consider fungal pneumonias as a possible cause of respiratory illness, particularly if COVID-19 testing is negative. It is important to note that these fungal diseases can occur at the same time as COVID-19.<sup>[22](#),[23](#)</sup>

# Miscellaneous

[Invasive pulmonary fusariosis in an immunocompetent critically ill patient with severe COVID-19.](#)

Poignon C, Blaize M, Vezinet C, Lampros A, Monsel A, Fekkar A.  
Clin Microbiol Infect. 2020 Nov;26(11):1582-1584. doi:  
10.1016/j.cmi.2020.06.026. Epub 2020 Jun 30.

[Promising effect of in-situ lyticase enzyme therapy on peritoneal dialysis catheter obstruction from \*Acremonium\* fungal biofilm: A case report](#)

[Thana Thongsricome<sup>1</sup>, Talerngsak Kanjanabuch<sup>1,2,3</sup>, Nopparat Maeboonruen<sup>3</sup>, Preeyarat Pavatung<sup>2</sup>, Pisut Katavetin<sup>1,3</sup>, Somchai Eiam-Ong<sup>1</sup>](#)  
Med Mycol Case Rep . 2020 Dec;30:26-28. doi: 10.1016/j.mmcr.2020.09.006.

[Identification by Matrix-Assisted Laser Desorption Ionization-Time of Flight Mass Spectrometry and Antifungal Susceptibility Testing of Non-Aspergillus Molds.](#)Li Y,

Wang H, Hou X, Huang JJ, Wang PC, Xu YC.

Front Microbiol. 2020 Jun 3;11:922. doi: 10.3389/fmicb.2020.00922. eCollection 2020.PMID: 32582045

# References

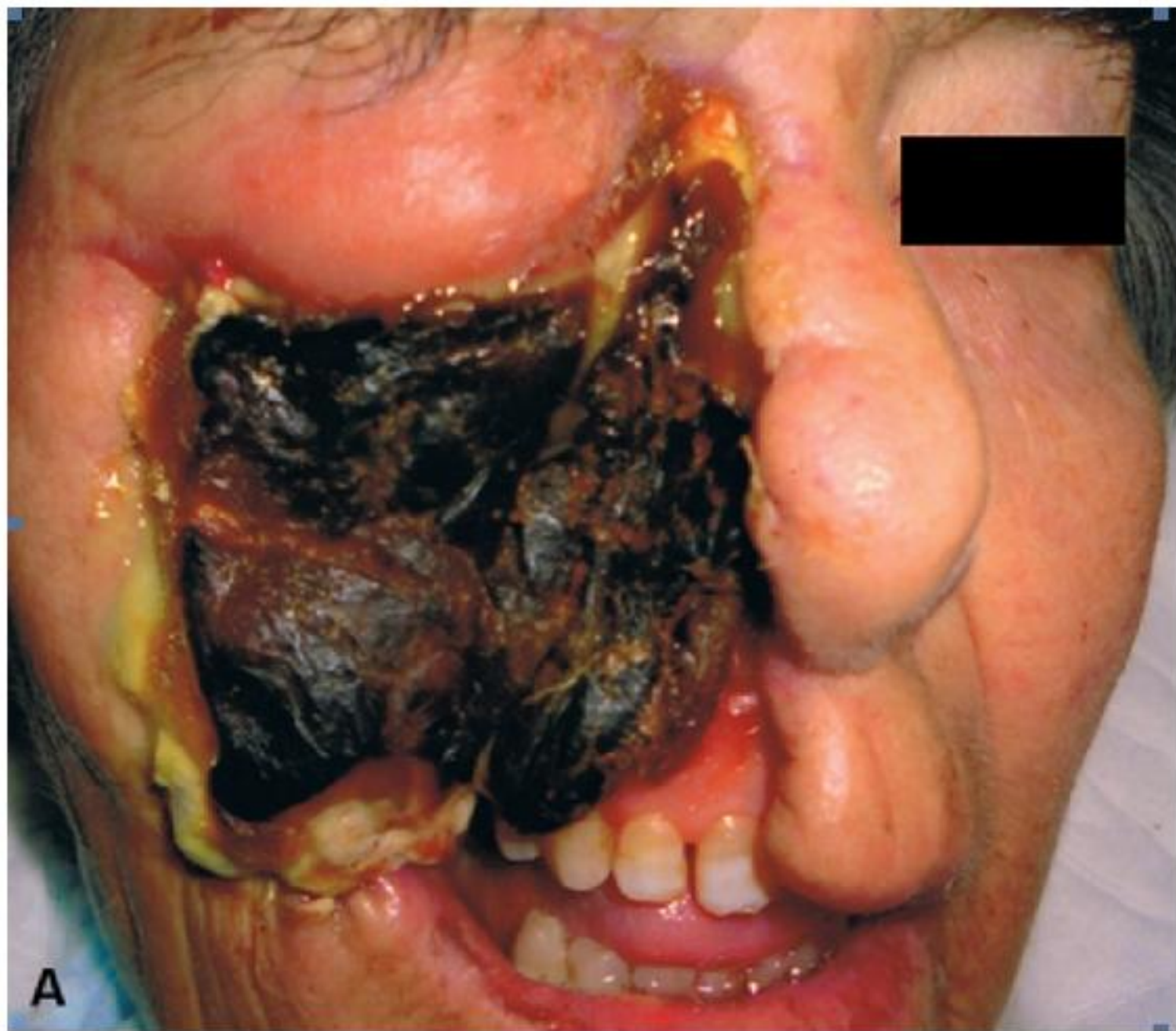- Hoenigl M. [Invasive fungal disease complicating COVID-19: when it rains it poursexternal icon](#). Clin Infect Dis. 2020 Sep 5
- Garcia-Vidal C, Sanjuan G, Moreno-García E, et al. [Incidence of co-infections and superinfections in hospitalized patients with COVID-19: a retrospective cohort studyexternal icon](#). Clin Microbiol Infect. 2020 Jul 31
- Lansbury L, Lim B, Baskaran V, Lim WS. [Co-infections in people with COVID-19: a systematic review and meta-analysisexternal icon](#). J Infect. 2020 May 27
- Gangneux JP, Bougnoux ME, Dannaoui E, Cornet M, Zahar JR. [Invasive fungal diseases during COVID-19: We should be preparedexternal icon](#). J Mycol Med 2020 Jun
- Song G, Liang G, Liu W. [Fungal co-infections associated with global COVID-19 pandemic: A clinical and diagnostic perspective from Chinaexternal icon](#). Mycopathologia. 2020 Jul 31
- Koehler P, Cornely OA, Böttiger BW, Dusse F, Eichenauer DA, Fuchs F, et al. [COVID-19 associated pulmonary aspergillosisexternal icon](#). Mycoses. 2020 May 15
- Chen N, Zhou M, Dong X, Qu J, Gong F, Han Y, et al. [Epidemiological and clinical characteristics of 99 cases of 2019 novel coronavirus pneumonia in Wuhan, China: a descriptive studyexternal icon](#). Lancet. 2020 Jan 30
- Beer KD, Jackson BR, Chiller T, Verweij PE, Van de Veerdonk FL, Wauters J. [Does pulmonary aspergillosis complicate COVID-19?external icon](#) Crit Care Exp. 2020 Sep 18
- Mohamed A, Rogers TR, Talento AF. [COVID-19 associated invasive pulmonary aspergillosis: diagnostic and therapeutic challengesexternal icon](#). J Fungi. 2020 Jul 22
- Verweij PE, Gangneux J, Bassetti M, Bruggemann RJM, Cornely OA, Koehler P, et al. [Diagnosing COVID-19-associated pulmonary aspergillosisexternal icon](#). Lancet Microbe. 2020 May 10
- Koehler P, Bassetti M, Chakrabarti A, Chen SCA, Colombo AL, Hoenigl M, et al. [Defining and managing COVID-19-associated pulmonary aspergillosis: the 2020 ECMM/ISHAM consensus criteria for research and clinical guidanceexternal icon](#). Lancet. 2020 Dec 14
- Dellière S, Dudoignon E, Fodil S, Voicu S, Collet M, Oillic P, et al. [Risk factors associated with Covid-19-associated pulmonary aspergillosis in ICU patients: a French multicentric retrospective cohortexternal icon](#). Clin Microbiol Infect. 2020 Dec 13
- Marr KA, Platt A, Tornheim JA, Zhang SX, Datta K, Cardozo C, et al. [Aspergillosis complicating severe coronavirus disease](#). Emerg Infect Dis. 2021 Jan
- Benedetti MF, Alava KH, Sagardia J, et al. [COVID-19 associated pulmonary aspergillosis in ICU patients: Report of five cases from Argentinaexternal icon](#). Med Mycol Case Rep. 2020 Dec 7
- Arastehfar A, Carvalho A, van de Veerdonk, FL, Jenks JD, Koelher P, Krause R, et al. [COVID-19 associated pulmonary aspergillosis \(CAPA\) – from immunology to treatmentexternal icon](#). 2020 Jun 24
- [CDC: Information for Healthcare Professionals About Aspergillosis](#)
- Nucci M, Barreiros G, Guimarães LF, Deriquehem VA, Castiñeiras AC, Nouér SA. [Increased incidence of candidemia in a tertiary care hospital with the Covid-19 pandemicexternal icon](#). Mycoses. 2020 Dec 4
- Hughes S, Troise O, Mughal N, Moorse LSP. [Bacterial and fungal coinfection among hospitalized patients with COVID-19: a retrospective cohort study in a UK secondary-care settingexternal icon](#). Clin Microbiol Infect. 2020 Jun 27
- Posteraro B, Torelli R, Vella A, Leone PM, De Angelis G, De Carolis E, et al. [Pan-echinocandin-resistant Candida glabratabloodstream infection complicating COVID-19: a fatal case reportexternal icon](#). J Fungi. 2020 Sep 6
- Meijer EFJ, Dofferhoff ASM, Hoiting O, Buil JB, Meis JF. [Azole-resistant COVID-19-associated pulmonary aspergillosis in an immunocompetent host: a case reportexternal icon](#). J Fungi. 2020 Jun 6
- Benedict K, Kobayashi M, Garg S, Chiller T, Jackson BR. [Symptoms in blastomycosis, coccidioidomycosis, and histoplasmosis versus other respiratory illnesses in commercially insured adult outpatients, United States, 2016–2017external icon](#). Clin Infect Dis. 2020 Oct 16
- Shah AS, Heidari A, Civelli VF, Sharma R, Clark CS, Munoz AD, et al. [The coincidence of 2 epidemics, coccidioidomycosis and SARS-CoV-2: a case reportexternal icon](#). J Investig Med High Impact Case Rep. 2020 Jun 4
- Bertolini M, Mutti MF, Barletta JA, et al. [COVID-19 associated with AIDS-related disseminated histoplasmosis: a case reportexternal icon](#). Int J STD AIDS. 2020 Sep 9
- Rabagliati R, Rodríguez N, Núñez C, Huete A, Bravo S, Garcia P. [COVID-19-Associated Mold Infection in Critically Ill Patients, Chile](#). Emerging infectious diseases. 2021 May
- Garg D, Muthu V, Sehgal IS, Ramachandran R, Kaur H, Bhalla A, et al. [Coronavirus Disease \(Covid-19\) Associated Mucormycosis \(CAM\): Case Report and Systematic Review of Literatureexternal icon](#). Mycopathologia. 2021 Feb 5
- Kanwar A, Jordan A, Olewiler S, Wehberg K, Cortes M, Jackson BR. [A Fatal Case of Rhizopus azygosporus Pneumonia Following COVID-19external icon](#). Journal of Fungi. 2021 Feb 28
- Cornely OA, Alastruey-Izquierdo A, Arenz D, et al. [Global guideline for the diagnosis and management of mucormycosis: an initiative of the European Confederation of Medical Mycology in cooperation with the Mycoses Study Group Education and Research Consortiumexternal icon](#). The Lancet Infectious diseases. 2019 Nov 4

از

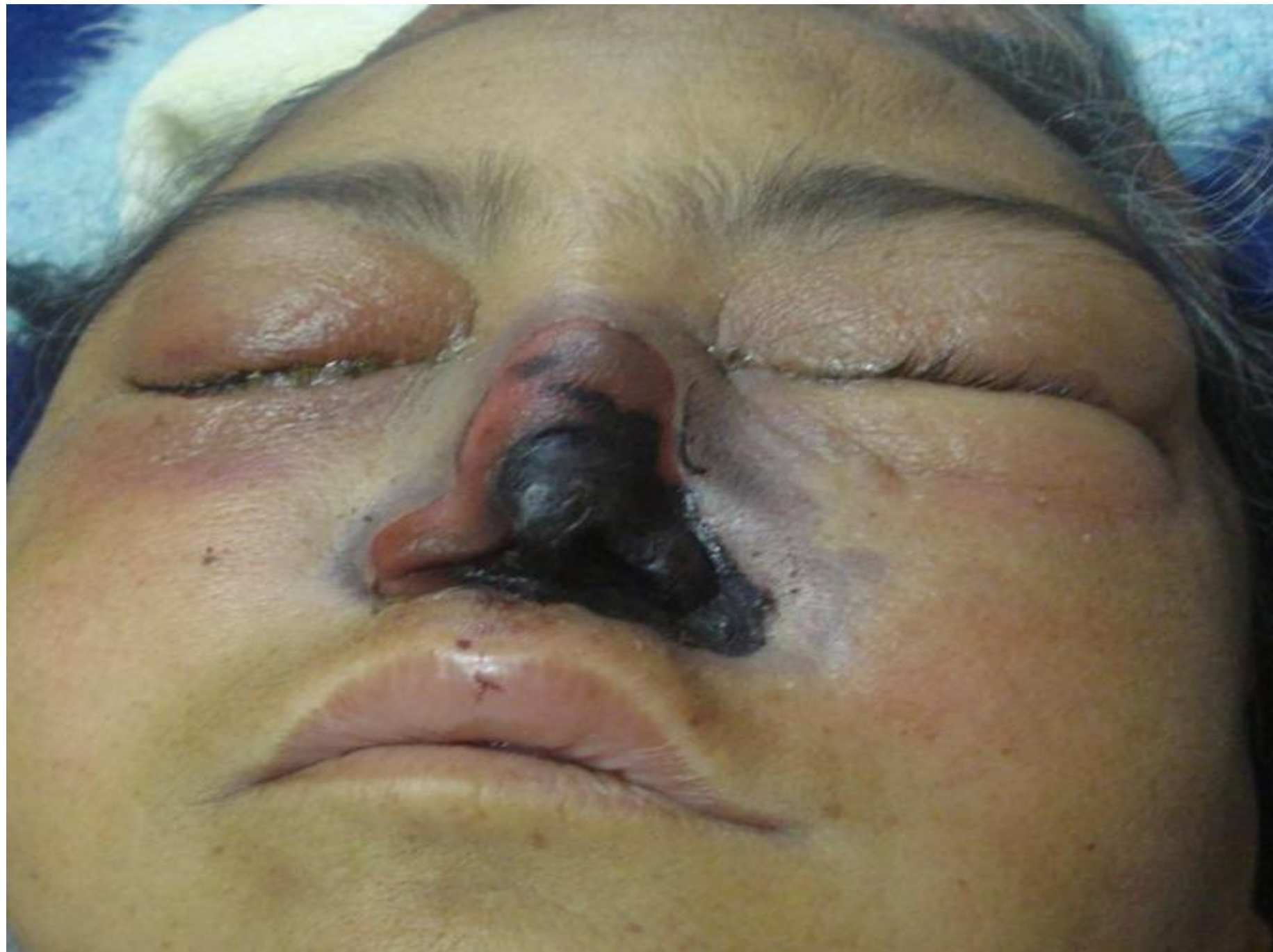توجه

شما

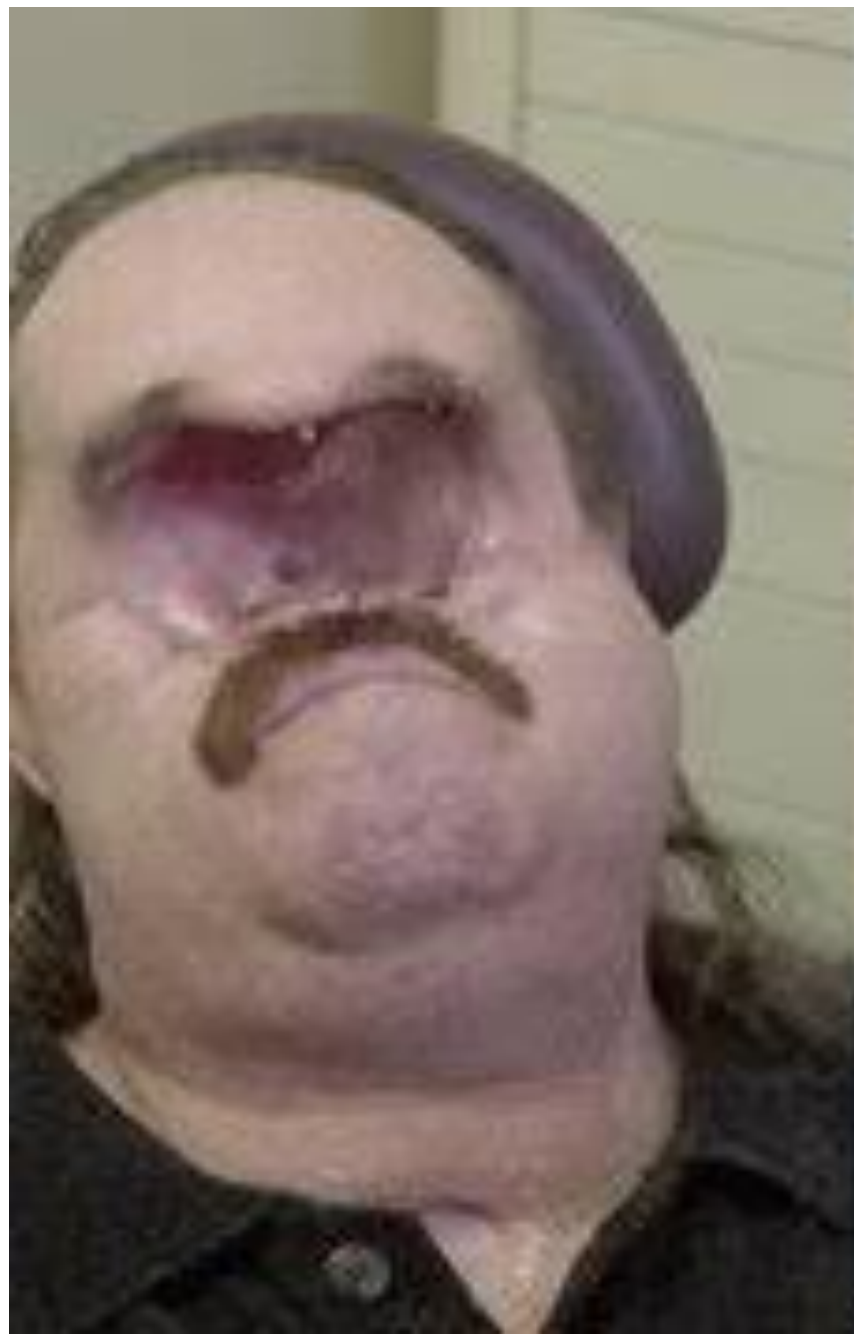سپاسگزارم

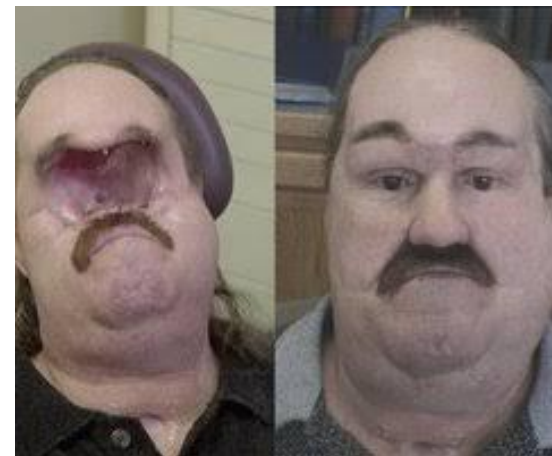


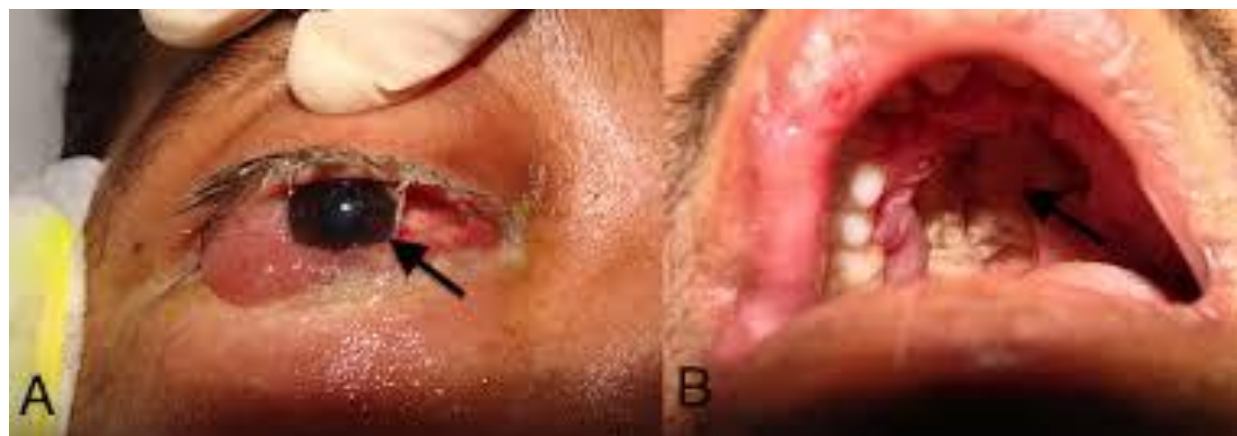
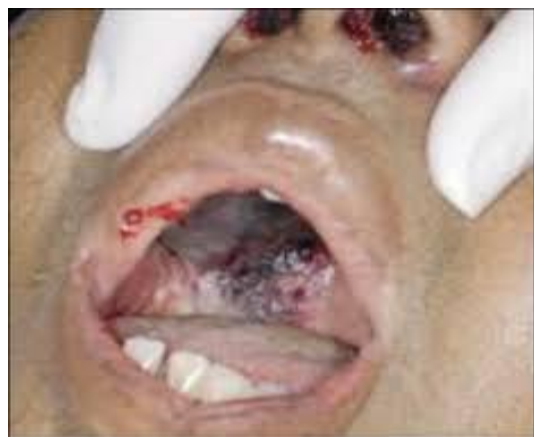
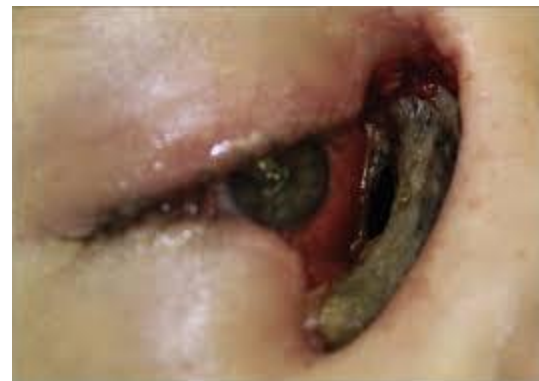
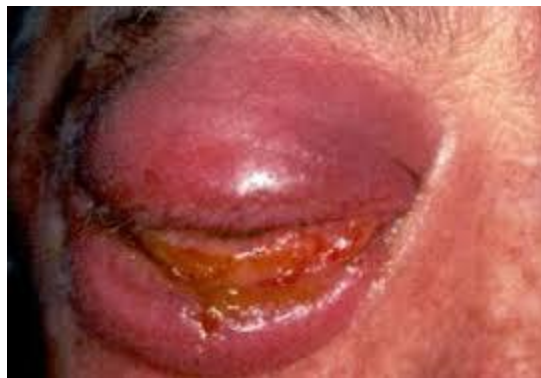







Photograph by Leslie Schreck

از

توجه

شما

سپاسگزارم

# **Fungal Diseases and COVID-19**